


PRESENTING CLINICAL SIGNS

History: Grade 4/6 murmur. Intermittent cough, dyspneic when in lateral recumbency. Radiographs on 3/2/23 showed moderate cardiomegaly. Currently receiving butorphanol and doxycycline.

DATE

3/28/23

ECHOCARDIOGRAPHIC FINDINGS

2D, M-mode, and Doppler study.

PERFORMED BY:

Kelly Vazquez

INTERPRETED BY

 Keith Blass, DVM,
 MS, DACVIM
 (Cardiology)

There is mild left atrial dilation. The mitral valve leaflets are thickened and exhibit systolic prolapse. A mild to moderate jet of eccentric mitral regurgitation is present. Left ventricular dimensions are normal. Left ventricular systolic function is hyperdynamic. The aorta and aortic valve are normal. Right atrial and right ventricular dimensions are normal. The tricuspid valve appears normal, though trace tricuspid regurgitation is present. The pulmonary artery and pulmonic valve appear normal, though trace pulmonic insufficiency is present. No shunting lesions are visualized. No heartworms are visualized. No pericardial effusion or cardiac masses are seen.

PATIENT

Lani Blau

LA - 30.3 mm
 LVIDd - 26.4 mm
 LVIDs - 12.7 mm
 FS - 51.9%
 RA - 19.3 mm
 LVOT - 1.70 m/s
 RVOT - 0.95 m/s

SPECIES

Canine

ASSESSMENT/RECOMMENDATIONS

Degenerative mitral valve disease

BREED

Chihuahua

This examination demonstrates mild to moderate regurgitation of blood across Lani's mitral valve resulting from degenerative valve disease. Secondary to her regurgitation, Lani has mild dilation of her left atrium, though her left ventricular dimensions are normal, and her left ventricular systolic function is well-preserved. As only mild left atrial dilation is present, it's unlikely that Lani's mitral valve disease is contributing to her cough, and her dyspnea when in lateral recumbency is unlikely to be cardiogenic in origin, especially considering that pulmonary edema was not evident in Lani's radiographs.

SEX

FS

I recommend starting Lani on pimobendan (2.5 mg am, 1.25 mg pm), as this medication should help to slow the progression of her mitral valve disease.

AGE

13 y

A recheck echocardiogram is recommended in 6-9 months. Repeat radiographs are recommended if clinical signs compatible with congestive heart failure develop.

WEIGHT

16 lb

HOSPITAL NAME

The Venturing Vet

REFERRING VET

Dr. Herzog



DATE

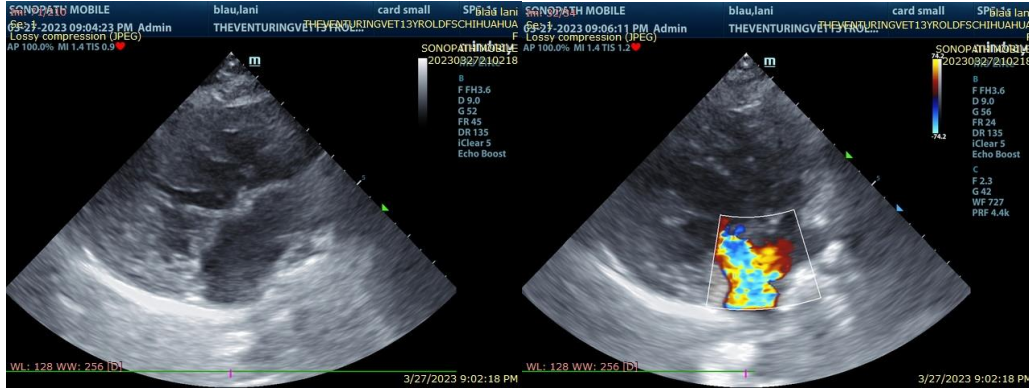
3/28/23

PERFORMED BY:

Kelly Vazquez

INTERPRETED BY

Keith Blass, DVM,
MS, DACVIM
(Cardiology)



The information and recommendations provided are based on the images presented by the referring veterinarian. No evaluation can be communicated regarding pathology that was not visible in the image/video clips provided.

PATIENT

Lani Blau

Thank you for this referral. If the clinical or image interpretation does not parallel your findings or if I can be of any further assistance please contact me.

SPECIES

Canine

Keith Blass, DVM, MS, DACVIM (Cardiology)
KeithBlass@gmail.com
631-804-5754

BREED

Chihuahua

SEX

FS

AGE

13 y

WEIGHT

16 lb

HOSPITAL NAME

The Venturing Vet

REFERRING VET

Dr. Herzog